



## ULTRASTRUCTURAL ASPECTS OF TWO MORPHOTYPES OF GRAM-NEGATIVE BACTERIA LOCATED IN THE ENDOMYSIUM OF THE SKELETAL MUSCLE OF *Trachurus trecae* (CARANGIDAE) IN ANGOLA

Aspectos ultraestruturais de dois morfotipos de bactérias gram-negativas localizadas no endomísio do músculo esquelético de *Trachurus trecae* (Carangidae) em Angola

Aspectos ultraestructurales de dos morfotipos de bacterias gramnegativas localizadas en el endomísio del músculo esquelético de *Trachurus trecae* (Carangidae) en Angola

Carlos Azevedo<sup>1\*</sup> , Nahyma Andrade<sup>2</sup>  & Graça Casal<sup>3,4</sup> 

<sup>1</sup> Laboratory of Animal Parasitology and Pathology, Interdisciplinary Centre of Marine and Environmental Research, University of Porto, Matosinhos, Portugal

<sup>2</sup> Department of Biology, Faculty of Natural Sciences, University Agostinho Neto, Luanda, Angola

<sup>3</sup> Toxicology Research Unit, University Institute of Health Sciences, Gandra, Portugal

<sup>4</sup> Laboratory of Cell Biology, Intitute of Biomedical Sciences, University of Porto, Porto Portugal

\*Author for corresponding: Azevedo, C., e-mail: azevedoc1934@gmail.com

### ABSTRACT

Ultrastructural and histopathological occasional parasite survey of some samples of the teleostean, *Trachurus trecae* (Carangidae), collected on the Atlantic coast of Angola were found infected by prokaryotic organisms identified as belonging to two morphotypes of Gram-negative bacteria located inside on extracellular space of the connective tissue of the endomysium among the skeletal muscle fibers. By serial ultrathin sections was observed that the majority of bacteria were cylindrical morphology, some appeared in division measuring  $2.8 \pm 0.7 \mu\text{m}$  long x  $0.9 \pm 0.3 \mu\text{m}$  in diameter, other having spherical form measuring  $2.8 \pm 0.4 \mu\text{m}$  in diameter. The ultrastructural organization of the myofibres contacting with of region where the bacteria were located, present the myofibrils ultrastructurally disorganized, without the typical muscular striations. The pathogenic effects of the two bacterial association seemed to give rise to the myofibrils lysis and concomitant disintegration and rupture of the wall of the muscle fibres, forming a recess where the bacteria live in close proximity. Muscle fiber wall in contact with the local where the bacteria were localized appeared lysed, disorganized and without the typical striations where, among them, some bacteria were observed. Some aspects of apparent penetration of bacteria through the degraded wall of the myofibers into the interior of the fibers, were observed and discussed. This is the first description of the pathogenic activity of bacteria in muscle tissue of a teleost from the aquatic fauna of Angola.

**Keywords:** fish, teleost, endomysium, bacteria, ultrastructure, histopathology.

### RESUMO

O levantamento ultraestrutural e histopatológico parasitário ocasional de algumas amostras do teleosteo, *Trachurus trecae* (Carangidae), coletadas na costa Atlântica de Angola, foram encontradas infectadas por organismos procarióticos, identificados como pertencentes a dois morfotipos de bactérias Gram-negativas localizadas no interior do espaço extracelular do tecido conjuntivo do endomísio entre as fibras musculares

ActaPesca 12(2), 2024

URL [www.actapescanews.com](http://www.actapescanews.com)

ISSN 2357-8068

DOI [10.46732/actafish](https://doi.org/10.46732/actafish)

Article

Submitted: Jul 18, 2024 / Accepted: Jul 31, 2024

Published: Sep 14, 2024

DOI: [10.46732/actafish.2024.12.2.104-109](https://doi.org/10.46732/actafish.2024.12.2.104-109)

esqueléticas. Por meio de cortes seriados ultrafinos observou-se que a maioria das bactérias apresentava morfologia cilíndrica, medindo  $2,8 \pm 0,7 \mu\text{m}$  de comprimento e  $0,9 \pm 0,4 \mu\text{m}$  de diâmetro, algumas apareciam em divisão, outras possuíam forma esférica, medindo  $2,8 \pm 0,4 \mu\text{m}$  de diâmetro. A organização ultraestrutural das miofibras em contato com a região onde as bactérias estavam localizadas, apresenta as miofibrilas ultraestruturalmente desorganizadas, sem as estrias musculares típicas. Os efeitos patogênicos das duas associações bacterianas pareciam dar origem à lise das miofibrilas e à concomitante desintegração e ruptura da parede das fibras musculares, formando um recesso onde as bactérias vivem próximas. A parede da fibra muscular em contato com o local onde as bactérias estavam localizadas apresentava-se lisada, desorganizada e sem as estrias típicas onde, entre elas, foram observadas algumas bactérias. Alguns aspectos da aparente penetração de bactérias através da parede degradada das miofibras para o interior das fibras foram observadas e discutidos. Esta é a primeira descrição da atividade patogênica de bactérias em tecido muscular de um teleosteo da fauna aquática de Angola.

**Palavras-chave:** peixes, teleosteos, endomísio, bactérias, ultraestrutura, morfotipos, histopatologia.

## RESUMEN

En el estudio ultraestructural e histopatológico de parásitos ocasionales de algunas muestras del teleosteo *Trachurus trecae* (Carangidae), recogidas frente a la costa atlántica de Angola, se observó que estaban infectadas por organismos procariotas, identificados como pertenecientes a dos morfotipos de bacterias Gram negativas localizadas en el interior del espacio extracelular del tejido conjuntivo endomísio entre las fibras musculares esqueléticas. Utilizando secciones seriadas ultrafinas, se observó que la mayoría de las bacterias tenían una morfología cilíndrica, que medía  $2,8 \pm 0,7 \mu\text{m}$  de longitud y  $0,9 \pm 0,4 \mu\text{m}$  de diámetro, algunas aparecían en división, otras tenían una forma esférica, que medía  $2,8 \pm 0,4 \mu\text{m}$  de diámetro. La organización ultraestructural de las miofibras en contacto con la región donde se localizaron las bacterias muestra miofibrillas ultraestructuralmente desorganizadas, sin las típicas estrias musculares. Los efectos patógenos de las dos asociaciones bacterianas parecían dar lugar a la lisis de las miofibrillas y a la desintegración y ruptura concomitantes de la pared de la fibra muscular, formando un receso donde las bacterias viven en estrecha proximidad. La pared de la fibra muscular en contacto con el lugar donde se encontraban las bacterias estaba lisada, desorganizada y sin las estrias típicas, entre las que se observaban algunas bacterias. Se observaron y discutieron algunos aspectos de la aparente penetración de las bacterias a través de la pared degradada de las miofibras hacia el interior de las fibras. Se trata de la primera descripción de la actividad patógena de bacterias en el tejido muscular de un teleosteo de la fauna acuática de Angola.

**Palabras clave:** peces, teleosteos, endomísio, bacterias, ultraestructura, morfotipos, histopatología.

## INTRODUCTION

Biological procaryotic microorganisms, particularly bacteria and rickettsia, are described as etiological agents of infectious diseases in a wide range of species of economic interest, mainly freshwater and marine fish (Apun et al., 1999; Padilla et al., 2001; Austin & Austin, 2012; El-Aamri et al., 2015; Silva et al., 2020; Petty et al., 2022), molluscs (Azevedo 1989; Azevedo & Villalba, 1991) and other taxonomic group (Thomaz et al., 1987). These microorganisms occur in varying conditions and are described as free agents (Azevedo et al., 2006; Banerjee & Ray, 2017; Hamed et al., 2018; Chai & Bi, 2022; Vanamala et al., 2022), as well as intracytoplasmic (Silva et al., 2020) or intranuclear agents (Azevedo, 1989). In some cases, co-infections of bacteria associated with rickettsiae are reported, constituting a lethal symbiosis (Azevedo & Villalba, 1991).

These microparasites occurring in different organs, are primary or opportunistic pathogens colonizing and causing disease and mortality in their hosts (Novotny et al., 2004; Austin and Austin, 2012; Novoslavskij et al., 2016; Hamed et al., 2018; Petty et al., 2022; Vanamala et al., 2022). Most infections of fish are caused by different genera of Gram-negative bacteria living vary, between intracellular (Silva et al., 2020; Mekasha & Linke, 2021; Chai & Bi, 2022) and an extracellular life (Azevedo & Villalba, 1991; Banerjee & Ray 2017; Mekasha & Linke, 2021). Bacteria isolated from fish constitute an important group of parasites and, in both situations, some can be pathogenic (Austin & Austin, 2012; Novoslavskij et al., 2016; Mekasha & Linke, 2021; Vanamala et al., 2022; Zaheen, 2022), others not causing any manifestation of histopathological effects living in symbiosis with their hosts (Banerjee & Ray 2017; Tarnecki et al., 2017). In the literature, rare occurrences of fish infected with bacteria are reported as potential sources of pathogens for humans (Novotny et al., 2004).

Some aspects of intracellular penetration of bacteria into different hosts, despite numerous descriptions, still has many unconfirmed suggestions, have been reported as result of the lytic activity of the penetrating bacteria (Gill & Penney, 1982; Thomas et al., 1987; Hamed et al., 2018).

In this microparasitological survey study reporting fish, we performed an ultrastructural study allowed the observation of the occurrence of endobiotic Gram-negative bacteria found in extracellular space among the myofibers (endomysium) and, simultaneously, other bacteria located among the degraded muscle myofibers of the collected fish in Atlantic coast of Angola.

## MATERIAL AND METHODS

### a) FISH SAMPLE

Five adult specimens (2 males and 3 females) of the teleostean *Trachurus trecae* Cadenat, 1950 (family Carangidae) (commun portuguese name “Carapau”) were captured in the Atlantic coast near the city of Luanda, Angola (08° 50' S; 13° 12' E) and transported on ice to the Laboratory of the University of Luanda, where it were dissected.

### b) LIGHT AND ULTRASTRUCTURAL EXAMINATION

For light microscopic (LM) surveillance, small fragments of the skeletal muscle, showed several assemblage of the prokaryotic spores, morphologically identified as belonging to bacteria. Living free bacteria, without staining, were photographed and measured. This observation allowed selecting the site of infection for later observation in transmission electronic microscopy (TEM), whose detailed procedures were followed in the LBC of ICBAS/UP (Azevedo, 1989; Azevedo & Villalba, 1991).

For TEM observations, small fragments of infected muscle were fixed in 3% glutaraldehyde buffered with 0.2 M sodium cacodylate (pH 7.2) for 4-5 h, washed overnight in the same buffer, and postfixed in 2% osmium tetroxide with the same buffer for 3 h. All these steps were operated at 4 °C. After dehydration in ascending ethanol series (50 to 100%) and propylene oxide (2 h in each two changes), the fragments were embedded in Epon (8-10 h in each change) and polymerized at 60-62 °C for 3 days. Semithin sections obtained by ultramicrotome were stained with methylene blue-Azure II for LM to detect the site of infection. Ultrathin sections were obtained with diamond knife, double-stained with uranyl acetate and lead citrate and examined with a Transmission Electron Microscopy (JEOL 100CXII TEM), operated at 60 kV.

## RESULTS

### a) LIGHT AND ULTRASTRUCTURAL OBSERVATIONS

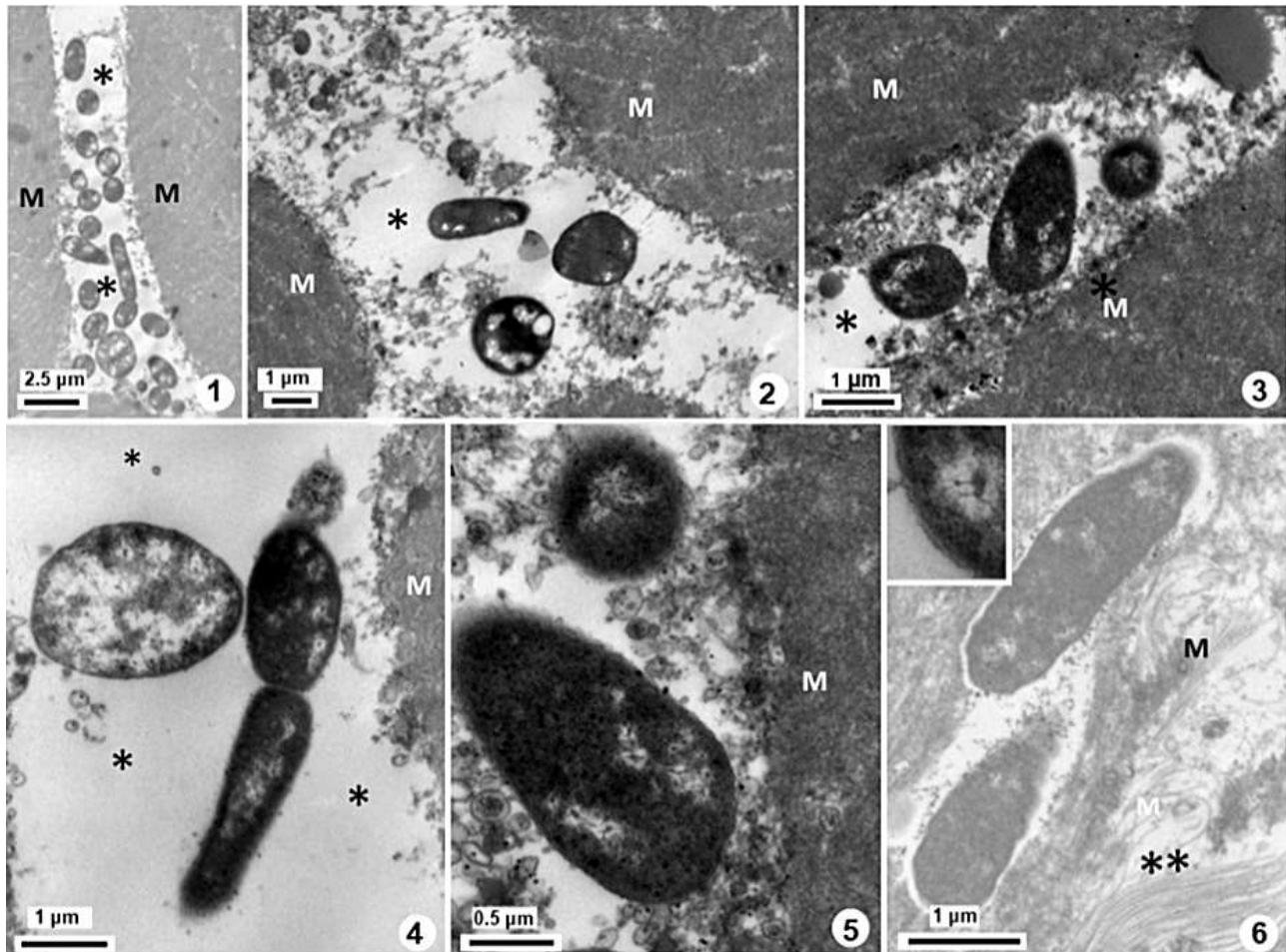
The main tissues and organs of the teleostean, *Trichurus trecae* (skeletal muscle tissue, gills, liver, gallbladder and digestive tract) were microparasitologically observed in an attempt to find any infection. Our attention was directed to the study of skeletal muscle tissue where several microorganisms identified as belonging to the group of Bacteria were observed, only place where the infection was found (Figure 1).

By LM observations the five specimens, only 3 of which (one male and two females) shown the skeletal muscle infected by numerous isolates bacterias observed by TEM, were located in the connective tissue of the endomysium (Figures 1-3). Among these bacterias two morphotypes were identified belonging to Gram-negative (Figures 4, 5). One type showed elongated cylindrical shape ( $4.2 \pm 0.7 \mu\text{m}$  long x  $1.0 \pm 0.4 \mu\text{m}$  in diameter) (n=15), while the other type spherical ( $1.8 \pm 0.4 \mu\text{m}$  in diameter) (n=25), measurements confirmed by serial ultrathin sections (Figures 1-5). Some of the cylindrical bacteria showed evident aspects of cell division (Figures 1, 4). The bacteria were grouped, but not agglutinate with variable number, placed relatively near to each other (Figures 1-5). The bacteria show chromatin organized under evidente anastomosed myofibers of DNA irradiating from several dense bodies randomly distributed among the aggregated dense masses of the chromatin (Figures 4, 5). These bacteria present several light areas among dense heterochromatin, where irregularly shaped electron-dense nodule was located from which radiate filamentous structures that anastomose to form a network. This network also radiates among the dense masses of heterochromatin (Figures 4, 5).

### b) HISTOPATHOLOGIC ASPECTS

Ultrastructural histopathology observations of the endomysium sites where the bacteria were located showed the muscle fiber wall near the bacteria, destroit and desorganized (Figure 3, 5). Several irregular dense masses occurring in the endomysium appear to be the result of degradation of the muscle fiber wall and

myofibrils (Figures 3, 5). Some aspects of the apparent penetration of bacteria from the endomysium into the myofibers were observed (Figure 5). The penetration was morphologically characterized by forming deep recesses in the myofiber wall where the bacteria were located (Figure 5). This phenomenon was observed through the wall of the muscular fibers that were degraded with aspects of rupture, where dense masses of irregular structure are observed, possibly resulting from contact between bacteria and the myofiber wall (Figure 5). Structure of the myofibers wall completely degraded, showing aspects of excision of the cytoplasmic debris of the adjacent myofibrils were observed in endomysium (Figure 6). Some isolated bacteria observed among desorganized myofibers, which show evident lysis, with the typical muscular striation showing complete disorganization were observed (Figures 6 and inset).



**Figures 1-6.** Ultrastructural aspects of two morphotypes of bacteria living in the endomysium (\*) among several myofibers of the muscle tissue (M) of the teleost *Trachurus trecae* collected on the Atlantic coast of Luanda (Angola):

1. Several bacteria living in the endomysium among muscle fibers; 2. Two type of bacteria sectioned at different level. 3. Some bacteria located in perimysium envolved by dense irregular masses seeming result of myofibers degraation. 4. A spherical bacteria near a long bacteria in evident stage of division; 5. Detail of two bactceria type in contact with myofiber that shows aspect de lysis. 6. Two bacteria in closed contact with the myofibrils showing evidente ultrastrutural desorganization, seeming bacterial penetration into periphery of myofiber; Inset: Ultrastructural detail of the spore wall, showing the Gram negative type.

## DISCUSSION

Morphological aspects of TEM observations showed that the presence of prokaryotic agents, as bacteria and rickettsia-like organisms, intracellularly infecting different host species has been frequently reported in several aquatic species of great economic interest (Azevedo et al., 2006; Silva et al., 2020; Mekasha & Linke, 2021; Zaheen, 2022). Most of them causing major problems of economic impacts, mainly, in aquacultures, where cause mortality and consequently, loss of production (Apun et al., 1999; Padilla et al., 2001; Austin, 2005; Austin & Austin, 2012; El-Aamri et al., 2015; Novoslavskij et al., 2016; Petty et al., 2022; Vanamala et al., 2022). However, in many of these descriptions, situations of pathogenicity or mortality due to the

interference of prokariotic microorganisms are not reported in some previously reported description (Apun et al., 1999; Austin & Austin, 2012; El-Aamri et al., 2015) while in others, they are reported as having symbiotic activities (Banerjee & Ray, 2017; Tarnecki et al., 2017).

The presence of several bacteria observed in the endomysium to skeletal muscle located close to the skin suggests that this phenomenon corresponds to a first phase of penetration from the environmental position of the bacteria to into the endomysium of the host, which was not observed in this study. However, the apparent aspect of penetration into the myofiber wall for direct contact with the myofibers, suggests that it corresponds to a second phase of penetration in which bacteria penetrate to the myofibers. The ultrastructural aspects of the bacteria observed in this study, and the supposed transit of bacteria from the endomysium to the interior of the myofibers, suggest that they are in line with the descriptions of similar phenomena described in various types of tissues and organs (Gill & Penney, 1982; Thomaz et al., 1987; Walczak et al., 2017; Hamed et al., 2018; Chai & Bi, 2022).

In the literature several phenomena have been reported related to the bacterial production of enzymatic systems that provide the digestion of several barriers allowing the penetration of the infecting bacteria (Gill & Penney, 1982; Thomas et al. 1987; Austin & Austin 2012; Petty et al. 2022) phenomenon that were not possible to observe in this study.

This work corresponds to first ultrastructural description of bacteria occurring in species of the ichthyological fauna of the Angolan coast.

## ACKNOWLEDGEMENTS

This study is original and was conducted in accordance with current legislation in the two countries where it was carried out. We appreciate the partial support given to our projects by Eng<sup>o</sup>. António de Almeida Foundation, Porto, Portugal, as well as the assistance of the technicians of the Laboratory of Cell Biology of the Institute of Biomedical Sciences, University of Porto, Porto, Portugal and of the Department of Biology of the University Agostinho Neto, Luanda Angola.

## REFERENCES

- Apun, K., Yusof, AM. & Jugang, K. (1999). Distribution of bacteria in tropical freshwater fish and ponds. *International Journal of Environmental Health Research*, 9(4): 285–292.
- Austin, B. (2005). Bacterial Pathogens of Marine Fish. In: Belkin, S. Colwell, R.R. (eds) *Oceans and Health: Pathogens in the Marine Environment*. Springer, Boston, MA. [https://doi.org/10.1007/0-387-23709-7\\_17](https://doi.org/10.1007/0-387-23709-7_17)
- Austin, B. & Austin, DA. (2012). Diseases of Farmed and Wild Fish. In: *Bacterial Fish Pathogens*, Springer, Dordrecht. London, 457 pp.
- Azevedo, C. (1989). Fine structure of endonucleobiotic bacteria in gill epithelium of *Ruditapes decussatus* (Mollusca, Bivalvia). *Marine Biology*, 100: 339-341.
- Azevedo, C., Conchas, RF., Tajdari, J. & Montes, J. (2006). Ultrastructural description of new Rickettsia-like organisms in the commercial abalone *Haliotis tuberculata* (Gastropoda, Haliotidae) from the NW of Spain. *Diseases of Aquatic Organisms*, 71: 233-237.
- Azevedo, C. & Villalba, A. (1991). Extracellular giant rickettsiae associated with bacteria in the gill of *Crassostrea gigas* (Mollusca, Bivalvia). *Journal of Invertebrate Pathology*, 58: 75-81.
- Banerjee, G. & Ray, AK. (2017). Bacterial symbiosis in the fish gut and its role in health and metabolism. *Symbiosis*, 72: 1–11.
- Chai, Z. & Bi, H. (2022). Capture and identification of bacteria from fish muscle based on immunomagnetic beads and MALDI-TOF MS. *Food Chemist.*, 13: 100225. doi: 10.1016/j.fochx.2022.100225
- El-Aamri, F. Caballero, MJ. Real, F. Acosta, F. Déniz, S. Román, L. & Padilla, D. (2015). *Streptococcus iniae* in gilthead seabream (*Sparus aurata* L.) and red porgy (*Pagrus pagrus* L.): ultrastructural analysis. *Veterinary Pathology*, 52(1): 209-212.
- Gill, CO. & Penney, N. (1982). Bacterial penetration of muscle issue. *Journal of Food Science*, 47: 690-691.

- Hameda, SB. Ranzani-Paiva, MJT. Tachibana, L. Dias, DC. Ishikawa, CM. & Esteban, MA. (2018). Fish pathogen bacteria: Adhesion, parameters influencing virulence and interaction with host cells. *Fish & Shellfish Immunology*, 80: 550-562.
- Mekasha, S. & Linke, D. (2021). Secretion systems in Gram-negative bacterial fish pathogens. *Frontiers of Microbiology*, 12: 1-28. <https://doi.org/10.3389/fmicb.2021.782673>
- Novoslavskij, A. Terentjeva, M. Eizenberga, I. Valciņa, O. Bartkevičs V. & Bērziņš, A. (2016). Major foodborne pathogens in fish and fish products: a review. *Annals of Microbiology*, 66: 1–15.
- Novotny, L. Dvorska, L. Lorencova, A. Beran, V. & Pavlik, I. (2004). Fish: a potential source of bacterial pathogens for human beings. *Veterinary of Medicine Czech*, 49(9): 343–358.
- Padilla, D. Acosta, F. Rodriguez, F. Gómez, V. Déniz, S. & Real, F. (2001). Mortality caused by *Staphylococcus xylosum* in red porgy (*Pagrus pagrus*) fish. *Journal of Applied Animal Research*, 19: 203-208.
- Petty, BD. Francis-Floyd, R. & Yanong, RPE. (2022). Bacterial Diseases of Fish. MSD Veterinary Manual.
- Silva, TJ. Casal, G. Soares, E. Rocha, S. Santos, EL. Oliveira, E. & Azevedo, C. (2020). Ultrastructure of intracytoplasmic Rickettsia-like infection of the gills of the teleost *Archosargus probatocephalus* (Sparidae) in northeastern Brazil. *Brazilian Journal of Veterinary Parasitology*, 29: e010020. <http://dx.doi.org/10.1590/s1984-29612020067>
- Vanamala, P. Sindhura, P. Sultana, U. Vasavilatha, & Gul, MZ. (2022). Common bacterial pathogens in fish: An overview. Bacterial Fish Diseases, Chapter 14, Academic Press, p. 279-306. [doi.org/10.1016/B978-0-323-85624-9.00010-5](https://doi.org/10.1016/B978-0-323-85624-9.00010-5)
- Tarnecki, AM. Burgos, FA. Ray, CL. & Arias, CR. (2017). Fish intestinal microbiome: diversity and symbiosis unravelled by metagenomics. *Journal of Applied Microbiology*, 123(1): 2-17.
- Thomas, CJ. O'Rourke, RD. & McMeekin, TA. (1987). Bacterial penetration of chicken breast muscle. *Food Microbiology*, 4(1): 87-95.
- Zaheen, Z. War, AF. Ali, S. Yatoo, AM. Ali, MN. Ahmad, SBA. et al. (2022). Common bacterial infections affecting freshwater fish fauna and impact of pollution and water quality characteristics on bacterial pathogenicity. Bacterial Fish Diseases, Chapter 7 -133-154.